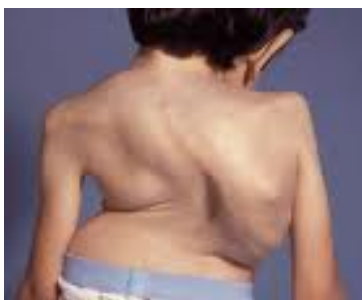

Scoliosis: A Three Dimensional Approach - Part A

By Linda McClure Structural Integrationist, MA Couns.

Probably one of the most easily remembered sufferers of scoliosis is Quasimodo. Victor Hugo popularized this character in his Novel 'The Hunchback of Notre Dame', first published in 1831. The story goes that Quasimodo was born with facial deformities and a severely hunched back. His horrified parents abandoned him on the steps of the Notre Dame Cathedral on Quasimodo Sunday, the first Sunday after Easter. He was found by the Archdeacon Claude Frollo, who adopts the baby, names him after the day the baby was found, and brings him up to be the bell-ringer of the cathedral. Despite Quasimodo's kind heart people could not get past his physical deformities and he was unfortunately, through ignorance, shunned and feared by the general populace of Paris.

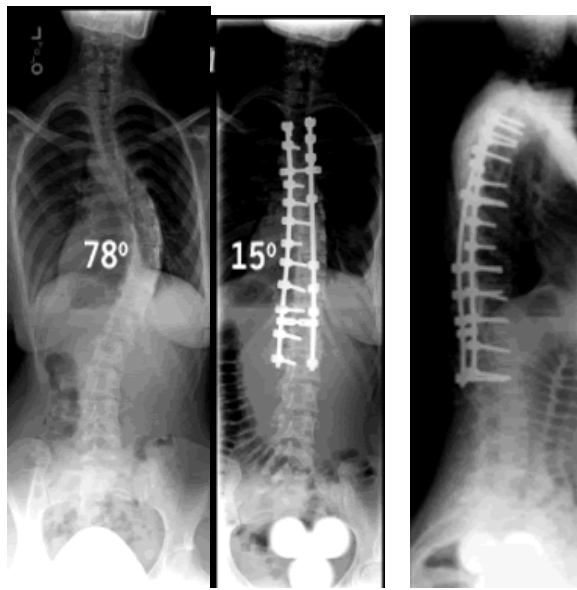
What is scoliosis then? We understand it medically as abnormal curvature (s) of the spine that can be complicated by not only lateral curvatures but also a kyphotic curvature, all organising around a helical like spiral. In these more severe cases it is called kyphoscoliosis which is what Quasimodo suffered. Most scoliosis we get to see is likely idiopathic scoliosis, which accounts for approximately 80% of cases. Idiopathic refers to a disease that has no known cause, yet the medical profession widely accepts that heredity or genetic factors account for the development of idiopathic scoliosis, which seems to be a contradiction in terms. They assume this because studies have documented scoliosis within families being more prevalent with relatives, than amongst the general population (Lowe et al 2000:1157). Yet to date there has been no gene found that is responsible for scoliosis so the jury is still out on exactly what factors are responsible for its occurrence.



Google Scholar Images 2010 Fig. 1

This slide shows a patient with lateral and sagittal curvatures uniting to create the most severe of scoliotic diagnosis, kyphoscoliosis. You can see the degree of compression and torsion that goes along with this condition, however we do not see the patient's face or the possible psychological distress living with this condition brings, but we can imagine.

Currently bracing and surgery are considered to be the only scientifically proven treatment methods for scoliosis, however you don't have to go far to see many other complimentary methods laying claim to improving the lot of those with scoliosis. Osteopathy, Massage, Muscle Energy techniques, Chiropractic, Structural Integration, Feldenkrais and the emerging therapy of Somatic Psychology to name a few.



"Copyright © 1996 - 2005, eSpine.com, Inc. All rights reserved" Fig 2

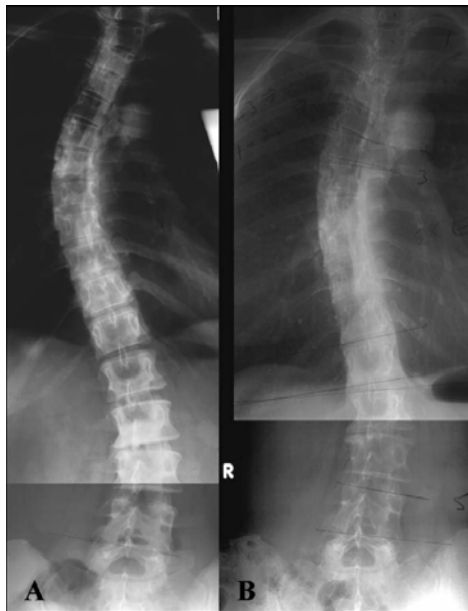This plate shows the hardware involved in spinal fixing for scoliosis. Be aware that now more than two thirds of this person's spine does not move. There is a law of physics that where stillness meets motion we get breakdown, so it is expected over time this person would have issues in their lumbar and cervical spine.

An Alternative Research Project

In the Journal of Psychosomatic Medicine, 2001, M Hawes Phd. published a case study of an adult patient (which turns out to be herself) whose own idiopathic scoliosis that had been fixed

and rigid for decades suddenly started to change during a period of psychological decompensation from post traumatic stress syndrome.

In response to excruciating back pain in December 1991 Hawes was prescribed an exercise program that included stretching, traction, massage therapy sessions and veiled references to cranial sacral therapy, myofascial release and trigger point therapy. Hawes had also taken part in individual and group psychotherapy sessions during that time that resulted in a personal emotional catharsis. This was in response to recalling repressed childhood memories springing out of her familial history of physical and emotional abuse and multigenerational family mental illness. From February 1992 through to April 1992 her thoracic curvature spontaneously improved from 47% to 28% and her lumbar curvature from 26% to 13%, with a chest expansion increase of 7.5cm, and a 2cm gain in height. According to Hawes this change was in response to the emotional release and subsequent integration of her past traumas.



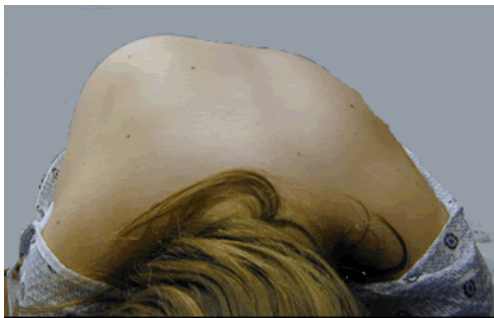Radiographs that show the change Hawes experienced in her Scoliosis (Brooks et al 2009:6) Fig 3

In her research Hawes found studies showed idiopathic scoliosis is correlated with psychological issues including a positive relationship between the degree of curvature and the degree of psychological disturbance, and increased suicidal thoughts amongst IS adolescents, compared

with the control group (Hawes & Brooks 2001:994), with the conclusion being that there is merit in looking at scoliosis not just as a physical concern but also a psychological one.

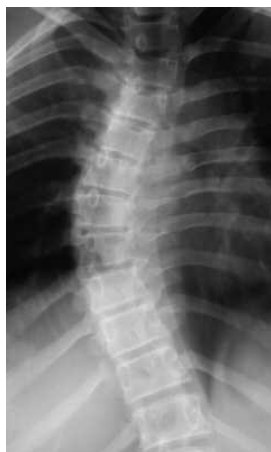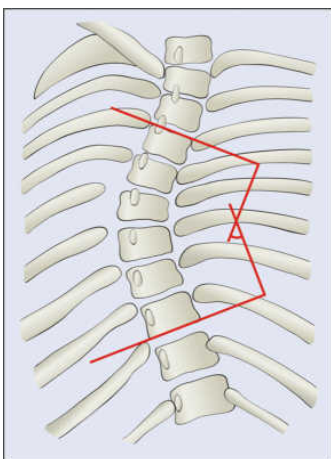
Part of the success of her project was to confirm that physical and manual therapies including massage (non-surgical/multimodal options) played a part in opening up her structure and likely set the stage for the successful psychological catharsis that began to shift her scoliosis.

Measuring Scoliosis



Google Images 2010 Fig 4

This forward Bend Test detects the rib hump that indicates the presence of scoliosis. Further measurements from X-rays will show more specifically the degree of scoliosis. We can calculate this by identifying the transitional vertebra, or the vertebra most superior and inferior to the curve that are the least displaced and rotated and have the maximally tilted end plate. A line is taken across these vertebrae and a right-angle is drawn from the superior and inferior positions until they intersect. We put our compass at the point of intersection and describe an arch – this measurement is the degree of scoliosis or **Cobb's Angle**. Because Cobb's angle reflects the curvatures only in a single plane it neglects to account for vertebral rotation so therefore does not show the severity of three dimensional spinal deformities.

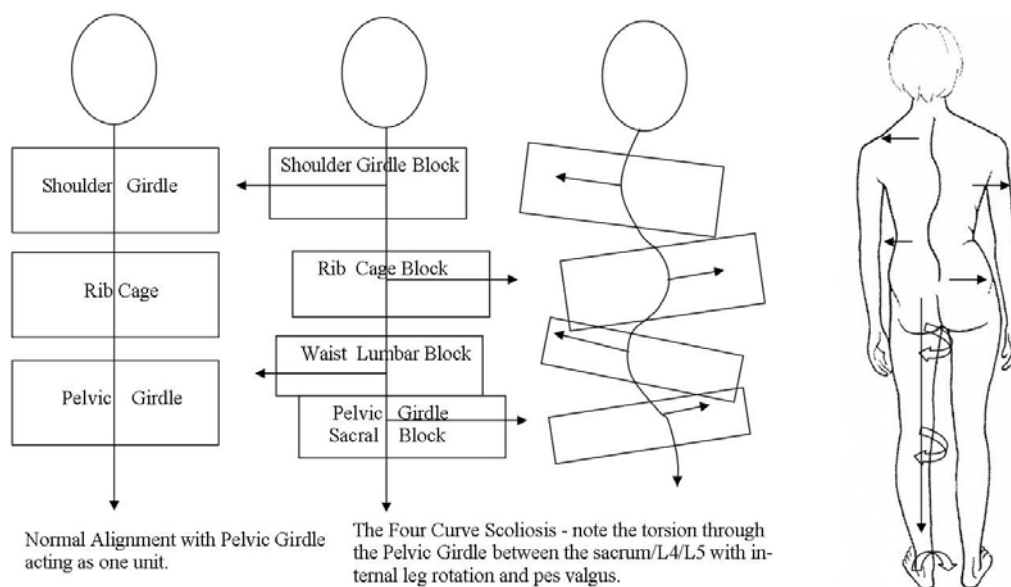


Cobbs Angle Google Images 2010 Fig 5

A little bit of History

Katharina Schroth was one of the earliest pioneers I could find that identified scoliosis as a three dimensional pathological development. She was far ahead of her time when she published her first booklet in 1924 where she details the importance of breathing exercises for scoliosis patients. She had scoliosis herself and developed her **rotational breathing and exercise program** after traditional treatment methods failed her. She meticulously detailed the three dimensional nature of scoliosis and noted where there was a flat area on the front of the ribcage there was a corresponding rib hump opposite on the back. By breathing in to the flat area she noticed the rib hump at the back decreased in size which meant by correcting the front she could simultaneously correct the back. Later she developed exercises that fixed the pelvis in an actively correct position and then had the patient performing trunk-elongating exercises that derotated the ribcage and straightened the spine which has a positive secondary effect on the breathing (Lehnert-Schroth 2007).

By considering scoliosis as a three dimensional issue we are then bound to observe this confounding condition is a whole body problem not only expressed in the superficial tissue but also in the deep core myofascia. Because the body is an integrated system misalignment in one area always produces a corresponding compensation elsewhere as the body negotiates verticality, locomotion, forward vision and gravity.



According to the Schroth Institute the Four Curve Scoliosis illustrated above has become more prevalent for some reason since the 1970's (Lenerth-Schroth 2007:65). It demonstrates the 4th curve in the L4/L5/Sacral block, and is referred to as the scoliotic pelvis by Lenerth-Schroth (2007:69), with waist, rib and shoulder blocks above. There are also one curve thoracic or lumbar scoliosis, various double curve forms and three curve scoliosis.

Understanding the Territory

Up to date X-rays can give us a visual description of a scoliosis, plus this clearly shows where the curvatures are. To simplify the understanding of these curvatures we see that in a normal structure we have three functional physiological curves, the lumbar lordosis, thoracic kyphosis and cervical lordosis. These form three segments or blocks of the trunk, a) lumbar spine and pelvis, b) thoracic spine and rib cage, c) cervical spine and shoulder girdle, as detailed in the plate above. Assessing the curvatures from a forward bend test is also helpful which will be part of your comprehensive visual assessment where it is important to note leg length differences, rotations, weight bearing vectors and compressions. If possible structural photographs against a wall grid are recommended to detail progress. This is useful for both practitioner and client.

We see the dysfunction of these curves as wedge shaped in the saggital plane, causing malposture such as the condition of lordosis or kyphosis which manifests if we look at the lateral view as the classic collapsed stated that often includes hyperextended knees.



Copyright © - all rights reserved *Quantum Health* Fig 7

In scoliosis we not only get the saggital displacement (front to back) but also due to lateral shifting (to the side) we find the displaced segments or blocks of the trunk become wedge like in both the lateral and saggital views creating at least three torsions of the trunk around the vertical

axis. In general we also find in response to the curvatures one leg internally rotating and functionally shortening with the gluteals having high tonus and pes valgus (collapsed arch) on the foot of same leg (see previous plate). There is also an out flare of the ilium on the opposite more prominent hip, and in general that whole side is weaker and less supported than the other.

In our next article we will look at some general treatment options from a Structural Integration approach.

References:

Hawes M.C. Phd, 2001, 'Improved Chest Expansion in Idiopathic Scoliosis after intensive multiple-modal, non-surgical treatments in an adult', *Journal of Psychosomatic Medicine*, Vol., 63, pp 994-995. Retrieved Google Scholar data base 12/02/2010.

Lehnert-Schroth C., 2007, Three Dimensional Treatment for Scoliosis, A Physiotherapeutic Method for Deformities of the Spine, Martindale Press, PaloAlto, California USA, www.schrothmethod.com

Lowe T.G., Edgar M., Margulies J.Y., Miller H.H., Raso J., Keinker K.A., Rivard C., 2000, 'Etiology of Idiopathic Scoliosis: Current Trends in Research, *The Journal of Bone and Joint Surgery Inc.*, Vol 82-A, No.8, pp 1157-1168. Retrieved ProQuest database 12/02/2010.